

See discussions, stats, and author profiles for this publication at: <https://www.researchgate.net/publication/380759235>

Should Rabies Vaccination in the Gluteus Muscle be Treated as Unimmunized ? – A Case Report

Article in APCRI Journal · May 2024

DOI: 10.24321/0973.5038.202401

CITATIONS

0

READS

179

4 authors, including:



Freston Marc Sirur
Manipal Academy of Higher Education

19 PUBLICATIONS 55 CITATIONS

SEE PROFILE



Omesh Kumar Bharti
Indira Gandhi Medical College

204 PUBLICATIONS 556 CITATIONS

SEE PROFILE

Case Report

Should Rabies Vaccination in the Gluteus Muscle be Treated as Unimmunized? - A Case Report

Vrinda Lath¹, Freston Marc Sirur², Ramya³, Omesh Kumar Bharati⁴

¹Senior Resident, ²Associate Professor, Department of Emergency Medicine, Kasturba Medical College, Manipal, Manipal Academy of Higher Education, Manipal, Karnataka, India.

³Emergency Medical Technology, Second Semester MSc EMT Student, Medical Technology, Manipal College of Health Professions, Manipal, Manipal Academy of Higher Education, Manipal, Karnataka, India.

⁴State Institute of Health & Family Welfare, Shimla, Himachal Pradesh, India.

DOI: <https://doi.org/10.24321/0973.5038.202401>

I N F O

Corresponding Author:

Omesh Kumar Bharati, State Institute of Health & Family Welfare, Shimla, Himachal Pradesh, India.

E-mail Id:

bhartiomesh@yahoo.com

Orcid Id:

<https://orcid.org/0000-0001-5178-1503>

How to cite this article:

Lath V, Sirur FM, Ramya, Bharati OK. Should Rabies Vaccination in the Gluteus Muscle be Treated as Unimmunized? - A Case Report. APCRI J. 2024; 26(1): 1-3.

Date of Submission: 2024-04-08

Date of Acceptance: 2024-05-20

A B S T R A C T

Rabies is a fatal disease with almost 100% mortality, with the recommended mainstay of management being preventive, post-exposure prophylaxis, and mass dog vaccination. In India, there have been many reports of failure of post-exposure prophylaxis, often due to administration, vaccine quality, and storage. One of the contributing factors is the gluteal administration of rabies vaccine. Here we discuss a case of a partially vaccinated child presenting on day 3 following a category 3 bite, with the first two doses administered intramuscularly in the gluteal region. This case highlights a conundrum faced by clinicians who often encounter partially vaccinated patients, which in this case was treated similarly to an unvaccinated case as the route of previous doses was gluteal.

Keywords: Rabies, Partial Vaccination, Gluteal Route

Introduction

Rabies is a fatal disease, prevalent in over 150 countries, including India, predominantly transmitted by dogs with an estimated 59,000 deaths annually.¹ India ranks among the highest in terms of disease burden with about 1.1 deaths per 100,000 population despite readily available post-exposure prophylaxis and mass dog vaccination.² It is associated with almost 100% mortality with a few survivors. Therefore, prevention remains the mainstay of rabies vaccination, with the One Health approach being the recommended practice.¹ It includes post-exposure prophylaxis and mass dog vaccination.

Although prophylaxis-seeking behaviour is one of the problems contributing to the high burden, another significant problem is vaccine failure.³ The intradermal

route of administration allows a more efficient utilization as compared to intramuscular but is limited by vaccination storage and administration practices. The intramuscular route, although effective, has also been associated with vaccine failure.³ A major challenge faced by clinicians is to remain up to date with the guidelines, while also managing partially treated cases where history is insufficient, or protocol deviation has been noted. We describe a case of a 12-year-old child who had presented on day 3 following a category 3 bite after receiving 2 doses of rabies vaccination, possibly intramuscularly in the gluteal region, without receiving rabies immunoglobulin. This situation presented the clinician with a conundrum.

1. Should post-exposure prophylaxis be continued, or should the child be treated as an unvaccinated case?
2. Is it okay to administer two doses of vaccine on the

same day?

3. If treated as unvaccinated, what route would be ideal?
4. Should rabies immunoglobulin be administered, and if yes, which site?

Case Report

A 12-year-old male child, with no known comorbidities, presented to the emergency medicine department of a tertiary healthcare centre in coastal Karnataka on March 30, 2024, on day 3 following a history of a dog bite.

The child was playing with a free-ranging 3-month-old unvaccinated puppy, following which the puppy inflicted multiple bite and scratch wounds over both ankles. Bleeding was noted from the bite sites. He immediately reported the incident and was taken to a local clinic where he was administered the '0' dose of anti-rabies vaccine (Rabivax-Vero cell vaccine), intramuscularly in the gluteal region, and tetanus toxoid in the left shoulder. He then followed up on March 30 for the second dose, which was administered intramuscularly in the gluteal region. The puppy was observed and was found to have passed away on the evening of March 30, and two other puppy deaths were also reported from the region. The concerned family brought him to our centre for review.

Examination and Management

The child's birth and developmental history were unremarkable. He was vaccinated appropriately as per the national immunization schedule and reported to have a good scholastic performance. He had received 4 doses of rabies prophylaxis 2 years earlier also, but other details were unavailable.

The child was hemodynamically stable with a normal systemic examination at presentation. Local examination revealed multiple healing abrasions and lacerations over the Achilles tendon region of the left ankle, and the medial malleolar region on the right, each measuring up to 1 cm in length (Figure 1). No puncture wound with active bleeding or discharge was noted at the time of examination.

The vaccination history was reaffirmed, but considering the possible gluteal administration, the bite being category 3, and the puppy having died the same day, the child was treated as an unvaccinated case, and 0.5 mL of Abhayrab (purified Vero cell vaccine) was administered in the right deltoid muscle. The family was requested to administer rabies monoclonal antibody (Rabishield), at 3.33 IU/kg, the dose being rounded off to 150 IU (3.75mL), of which 3 mL could be infiltrated around the bite wounds. The weight of the child was 44 kg. The remaining 0.75 mL of immunoglobulin was administered in the left deltoid muscle as recommended by the leaflet provided by the company.

The family was counselled regarding the need for follow-up and completion of the vaccination doses. In this case, the 5-dose intramuscular regimen was planned to be administered as per the current recommended national standard treatment guidelines.²

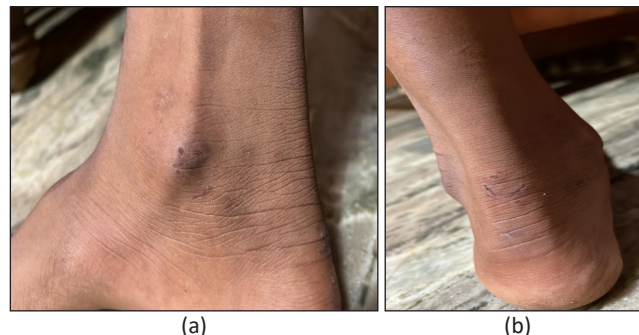


Figure 1. Bite Sites of (a) Right Ankle and (b) Left Ankle, Showing Partially Healed Abrasions and Lacerations, as Photographed on Day 3 Post-Bite

Discussion

Described above is a 12-year-old previously vaccinated child who had presented on day 3 following a category 3 dog bite to both ankles. Additionally, it was reported that the culprit dog had passed away and was not available for diagnostic testing, and therefore, could not be ruled out as a probable case of rabies.

This case highlights the importance of history taking, particularly the dose and route of rabies vaccine administration, which in this case, revealed possible gluteal intramuscular administration of the first two doses. Current guidelines recommend against this as there is a higher chance of injection into the adipose tissue in the subcutaneous plane, resulting in a suboptimal immune response.⁴⁻⁹ Therefore, it was considered advisable to treat the case as an unvaccinated case and revaccinate. The intramuscular regimen was followed as per institutional protocol, which is in line with the national standard treatment guidelines. Revaccination on the same day was administered, considering the possible ineffective gluteal dose that was administered earlier the same day.

As the patient presented within 7 days of initiation of vaccination, rabies immunoglobulin was infiltrated as per standard treatment guidelines.⁴ Although the child was vaccinated 2 years back, details were unavailable. This child was therefore treated as an unvaccinated case and immunized as per guidelines. While most of the rabies immunoglobulin was infiltrated around the bite site, the remaining dose was administered intramuscularly in the deltoid, although evidence for intramuscular injection is scarce.^{10,11} This was as per the recommendation by the leaflet provided by the company.² Gluteal regions were avoided as they were potential sites for vaccine failure.

Although India has advanced by leaps and bounds in achieving the goal of rabies elimination in response to the zero by 2030 call by the World Health Organization, there are still many gaps to address. This case highlights some such gaps, one being the lack of drive to trace and diagnose the biting animal, which in this case was a three-month-old puppy, which, along with nursing mothers, is not covered under the mass dog vaccination program.¹² The government has spent considerable time and resources in training healthcare providers, but a few in peripheries may not be covered under these programs. While diagnostic tests are available to test antibody titers, they are limited in availability and may not be reported on time. Another challenge is posed due to frequent changes in healthcare facilities by patients, as well as poor adherence to the vaccination dose regimen, often resulting in incomplete vaccination or delayed dose administration.

Conclusion

This case highlights one of the conundrums faced by healthcare providers, in the case of a patient with possible inadequate immunization. Considering available evidence, cases where vaccine effectiveness is doubtful should be treated as unvaccinated cases. This case also highlights the need for widespread awareness and effective communication and dissemination of evidence-based practices.

Acknowledgment

We thank the Department of Emergency Medicine, Kasturba Medical College, Manipal for providing the resources and support for managing the patient.

Conflict of Interest: The authors declare that there are no conflicts of interest.

References

- World Health Organization. Zero by 30: the global strategic plan to end human deaths from dog-mediated rabies by 2030. Geneva: WHO; 2018. [Google Scholar]
- National Rabies Control Programme. National guidelines on rabies prophylaxis. National Centre for Disease Control. Ministry of Health & Family Welfare, Govt of India; 2015.
- Thiagarajan K. Why did rabies control fail in India? *BMJ*. 2022;378:o2284. [PubMed] [Google Scholar]
- World Health Organization. Rabies vaccines: WHO position paper, April 2018–Recommendations. *Vaccine*. 2018.
- Soentjens P, Croughs M, Burm C, Declercq S, Clerinx J, Maniewski U, Broucke SV, Theunissen C, Huits R, Brosius I, Florence E, Kenyon C, Griensven JV, Ierssel SV, Lynen L, Balliauw K, Gucht SV, Esbroeck MV, Vlieghe E, Bottieau E, Herrewewege YV. Time of administration of rabies immunoglobulins and adequacy of antibody response upon post-exposure prophylaxis: a descriptive retrospective study in Belgium. *Acta Clin Belg*. 2021;76(2):91-7. [PubMed] [Google Scholar]
- Fishbein DB, Sawyer LA, Reid-Sanden FL, Weir EH. Administration of human diploid-cell rabies vaccine in the gluteal area. *N Engl J Med*. 1988;318(2):124-5. [PubMed] [Google Scholar]
- Chomchay P, Khawplod P, Wilde H. Neutralizing antibodies to rabies following injection of rabies immune globulin into gluteal fat or deltoid muscle. *J Travel Med*. 2000;7(4):187-8. [PubMed] [Google Scholar]
- Reid-Sanden FL, Fishbein DB, Stevens CA, Briggs DJ. Administration of rabies vaccine in the gluteal area: a continuing problem. *Arch Intern Med*. 1991;151(4):821. [PubMed] [Google Scholar]
- Bharti OK, Sharma V. Failure of postexposure prophylaxis in a patient given rabies vaccine intramuscularly in the gluteus muscle, Himachal Pradesh, India. *Indian J Crit Care Med*. 2018;22(3):189-90. [PubMed] [Google Scholar]
- Bharti OK, Anderson DC, Kishore J, Katoch P, Sharma P. Small volume of Rabies Immunoglobulin (RIG) is effective for local wound infiltration in rabies post-exposure prophylaxis whereas intramuscular RIG is just a wastage. *J Adv Res Med*. 2021;8(3):8-12. [Google Scholar]
- Bharti OK, Madhusudana SN, Gaunta PL, Belludi AY. Local infiltration of rabies immunoglobulins without systemic intramuscular administration: an alternative cost effective approach for passive immunization against rabies. *Hum Vaccin Immunother*. 2016;12(3):837-42. [PubMed] [Google Scholar]
- Bharti OK, Ramachandran V, Kumar SR, Phull A. Pup vaccination practices in India leave people to the risk of rabies — lessons from investigation of rabies deaths due to scratch/bite by pups in remote hilly villages of Himachal Pradesh, India. *World J Vaccines*. 2014;4(1):7-10. [Google Scholar]