

See discussions, stats, and author profiles for this publication at: <https://www.researchgate.net/publication/360102789>

Local Wound Spray of “Standardised Herbal Antibiotic Extract” on Snakebite Wounds along with Routine Anti Snake Venom Treatment Saves Lives, Limbs and Livelihood of Snakebite Victi...

Article · April 2022

DOI: 10.24321/2394.6547.202107

CITATIONS

0

READS

76

8 authors, including:



Omesh Kumar Bharti
Indira Gandhi Medical College

169 PUBLICATIONS 340 CITATIONS

[SEE PROFILE](#)



Archana Phull
Independent Researcher

26 PUBLICATIONS 48 CITATIONS

[SEE PROFILE](#)

Some of the authors of this publication are also working on these related projects:



Rabies in India [View project](#)



Intradermal rabies vaccination with local RIG infiltration in Bovine [View project](#)

Research Article

Local Wound Spray of “Standardised Herbal Antibiotic Extract” on Snakebite Wounds along with Routine Anti Snake Venom Treatment Saves Lives, Limbs and Livelihood of Snakebite Victims in Rural Maharashtra, India - 15 Case Reports as Pilot

Omesh Kumar Bharti¹, Sadanand Raut², Pallavi Raut², Lal Singh³, Arvind Kumar Bhatt⁴,
Nagesh Kumar Guleria⁵, Maninder Jeet Kaur⁶, Archana Phull⁷

¹PI, State Epidemiologist and Snakebite Expert, Shimla, Himachal Pradesh, India.

²I/C Vighnagar Nursing Home Clinic and Snakebite Expert, Pune, Maharashtra, India.

³Director cum Principal Scientist, ⁶Principal Scientist, Himalayan Research Group, Umesh Bhavan Chotta, Shimla, H. P., India.

⁴Professor and Head, Department of Biotechnology, HP University, Shimla, India.

⁵Chief Project Director, JIKA Project Himachal Pradesh, Shimla, India.

⁷Independent Researcher & Agriculture Economist, US Club, Shimla, Himachal Pradesh, India.

DOI: <https://doi.org/10.24321/2394.6547.202107>

I N F O

Corresponding Author:

Omesh Kumar Bharti, PI, State Epidemiologist and Snakebite Expert, Shimla, Himachal Pradesh, India.

E-mail Id:

bhartiomes@yaho.com

Orcid Id:

<https://orcid.org/0000-0001-5178-1503>

How to cite this article:

Bharti OK, Raut S, Raut P, Singh L, Bhatt AK, Guleria NK, Kaur JM, Phull A. Local Wound Spray of “Standardised Herbal Antibiotic Extract” on Snakebite Wounds along with Routine Anti Snake Venom Treatment Saves Lives, Limbs and Livelihood of Snakebite Victims in Rural Maharashtra, India - 15 Case Reports as Pilot. J Adv Res Ayur Yoga Unani Sidd Homeo. 2021;8(3&4): 7-14.

Date of Submission: 2021-10-14

Date of Acceptance: 2021-11-03

A B S T R A C T

Background: Globally between 81,000 and 138,000 people around the world die each year from snakebite. Authors noticed that the use of oral/ systematic antibiotics in many snakebite victims failed to heal the snakebite wounds, and either the patients required skin grafting or the bitten part developed necrosis and needed amputation.

Objectives: Authors after an extensive literature review thought of neutralising bacteria at the snakebite site by a potent antimicrobial spray, without any side effects.

Method: Authors decided to get the antimicrobial profile of herb X and found that it can neutralise the bacteria that are resistant even to the most potent antibiotics available.

Results: Herbal extract (234 ml) was prepared for pilot use in snakebite patients. A series of 15 patients were sprayed 2 puffs (7-10 ml) of ready to use herbal spray. None of them developed extensive blisters except the two patients who had mild blisters which resolved subsequently without any deep wound as used to be the case earlier.

Conclusion: This pilot project has shown promising results and needs to be applied in more cases in future.

Keywords: Snakebite, Herbal Spray, Blisters, Wound Management

Snakebite is an acute life-threatening time limiting medical emergency. Globally, each year, approximately 5.4 million people are bitten by snakes, of which 2.7 million are injected with venom. WHO estimates that the number of people who die all over the world each year due to snakebite range between 81,000 and 138,000 and up to 4 lakh are left permanently disabled or disfigured, as a result of being bitten by venomous snakes. In many communities, these permanent injuries result in people being discriminated against and ostracised, ultimately leading to a crippling loss of income, debt, mental health issues, and reduced quality of life.¹

India recorded a staggering 1.2 million snakebite deaths in the 20-year period from 2000 to 2019 with an average of 58,000 deaths caused by snakebite annually. Around 70% of these deaths occurred in limited, low altitude, rural areas of eight states - Bihar, Jharkhand, Madhya Pradesh, Odisha, Uttar Pradesh, Andhra Pradesh (including Telangana), Rajasthan and Gujarat. The study, conducted by the Centre for Global Health Research (CGHR) at the University of Toronto, Canada, with Indian and UK partners, also points out that half of all the snakebite deaths occurred during the monsoon period from June to September. The paper titled 'Trends in snakebite deaths in India from 2000 to 2019 in a nationally representative mortality study'² indicated that most of the envenomation (the process by which venom is injected by the bite or sting of a venomous animal) was by Russell's vipers followed by kraits and cobras. The study indicated that snakebite deaths occurred mostly in rural areas (97%), were more common in males (59%) than females (41%), and peaked at productive ages of 15-29 years (25%). The numbers for annual snakebite deaths were highest in the states of Uttar Pradesh (8,700), Andhra Pradesh (5,200), and Bihar (4,500), it further added.

Authors noticed in their clinical practice that the use of oral/systematic antibiotics in many snakebite victims failed to heal the snake bite wounds that led to swelling, blistering, sloughing and later, either the patients required skin grafting or the bitten part developed necrosis and needed amputation. Most of the patients get sloughing of the wound site within a week of being bitten by a snake. Authors after extensive literature review thought of neutralising bacteria at the snakebite site by a potent antimicrobial³ spray that is able to neutralise even the most resistant of bacteria. While biting snakes can not only inject pathogens through contaminated fangs but also through the micro-teeth⁴ present on both jaws of a snake's mouth that can contaminate the skin near the bite site by intradermal transfer of bacteria causing local infection and ulceration. As the swelling of the bitten part sets in a few hours after the bite, the blood supply is compromised making parental antibiotics inaccessible to the local bacteria deposited at the wound site.

The herb in question (Figure 1) though grown locally in Himachal Pradesh, India, has never been utilised traditionally for snakebite treatment⁵ but is mainly used for diabetes.⁶ The antimicrobial potential of herbal extract of a herb named "Swertiacordata" was being assessed by the Himalayan Research Group (HRG) Society, Shimla and looked promising. The chemical analysis report from the Biotechnology Department of Himachal Pradesh University had underlined the high potency antimicrobial activity of the herbal extract at 40 µl concentrations. The effectiveness of aqueous extract was studied against various pathogenic bacterial isolates i.e. Escherichia coli, Bacillus cereus, Salmonellatyphi, Staphylococcus aureus, Shigella flexneri, and Pseudomonas aeruginosa by agar well diffusion method and the antimicrobial activity of aqueous extract had the highest zone of inhibition at 40 microlitre concentration (Figure 2). A recent study⁷ has focused on the antioxidant, antibacterial, and antidiabetic potential of this herbal extract, however, we used it for snakebite as an innovation to minimise infection at the wound site. The herb in question is available for oral use for its anti diabetic properties as herbal medicine by various herbal pharma companies.⁸ This herb helps in quick healing of wounds, decreases swelling and brings back the normal texture of the skin. A paste of Chirata powder with coconut oil helps in quick healing and reduces inflammation due to its Ropan (healing) and Pitta balancing properties.⁹



Figure 1. Dried Parts of Herbal Plant

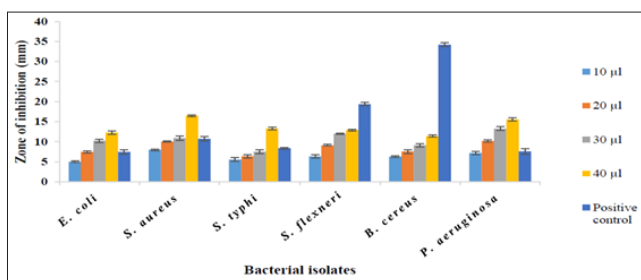


Figure 2. Antimicrobial Activity Graph of HE at Different Concentrations of HE

Method

This study was conducted between August 2021 and December 2021.

Aqueous Extraction

50 g of dried powdered material was added separately in 500 ml of distilled water in the ratio of 1:10 in a 500 ml flask and kept on a rotatory shaker for 72 hours at 35°C (130 rpm). The extract was filtered through Whatman No. 1 filter paper and air-dried at room temperature. The dried extract was collected and stored in a refrigerator at 4°C for further use. The effect of different concentrations of plant extract on various pathogenic isolates was observed by the agar well diffusion method and minimum inhibitory concentration (MIC) was determined by Resazurin based microtitre dilution method. Agar well diffusion method was used to assess the antimicrobial activity of various plant extracts. The antimicrobial compound present in the plant extract was diffused out into the medium to interact in a plate freshly seeded with the test organism. The resulting zones of inhibition appeared as uniform circular zones around the wells due to the confluent lawn at 37°C for 24 hrs.¹⁰ The diameter of the zone of inhibition is measured and is a mark of the extent of antimicrobial potential of that particular extract. The aqueous extract showed positive results against all the pathogenic isolates. The extract was found highly effective against many bacteria with inhibition at 40 µl conc. Chloramphenicol was taken as positive control for comparison.

25 gm/ml makes a concentration of 40 µl so 5.85 gm (5850 mg) dry extract was dissolved in 234 ml distilled water and used as a spray on snakebite wound skin area in 15 snake-bitten patients between the age group of 6 to 70 years who were presented to Vighnagar Nursing Home Clinic in Pune, Maharashtra.

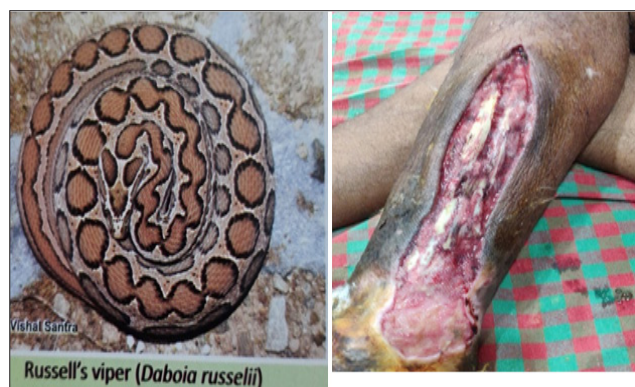Application of Herbal Extract as Spray

An empty spray bottle was sterilised and herbal extract powder was dissolved by gentle stir and was kept at 4 degree centigrade overnight for thorough mixing of plant ingredients in the water. The bite site was allowed to dry after routine cleaning with betadine and spirit. There after

skin at the bite site was stretched with thumb and the solution was stirred gently and sprayed on the snake-bitten area as two puffs with force and the spillover solution from the area was captured in a gauze piece kept below the sprayed area. This wet gauze was kept on the bite marks/bitten area for some time for better absorption of the antibiotic solution.

Results

Among the 15 patients, 11 were bitten by Russell's viper, two by common krait and one each by saw-scaled viper and green pit viper. All patients came to the clinic within 30 minutes to 3 hours after getting bitten. Apart from routine clinical treatment including ASV and parental antibiotics, all were sprayed with the herbal spray solution. Around 5 to 30 vials of ASV were used. None of them except two developed mild blisters and no sloughing of muscles in the bitten part was observed. All patients were discharged without skin grafting or amputation within 3-13 days of admission. Earlier, despite local cleaning of the bitten area with betadine and spirit, ASV and antibiotics use, blisters used to appear within five days, especially in cases bitten by Russell's viper (Figures 3 & 4). Now after addition of the herbal spray this time, all of them except two, had mild blisters (Figure 5) that resolved without a deep wound. All were saved from sloughing of the bitten part sparing them from skin grafting or amputation. Details of the patients are tabulated in Table 1.



Figures 3&4. Russell's Viper (Pic by Vishal Santra)¹¹ and its Bite Causing Sloughing of Tissues

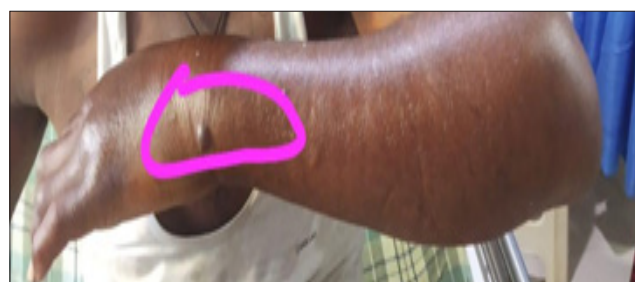

Figure 5. Small Blister in Case No. 15 (RV Bite) after Use of Herbal Spray that Resolved Spontaneously

Table I. Details of Patients

S. No.	Gender	Age (Years)	Bite to Spray Time (Hour(s))	Suspected Snake/ Pic/ Killed	Main Signs/ Symptoms	No. of ASV Vials Used	Blisters- Present/ Absent on Day 7	Outcome Normal/ Skin Graft/ Amputation	Discharge/ Death	Comments/ Spray Puffs Used-1/2/3
1.	M	21	3	R.V. bite	Pain, vomiting once, nausea, haematuria after 18 hrs, swelling up to knee joint in 3 hrs	15	Absent	7 days Normal	Discharge	2 times
2.	F	9	1.50	R.V. bite	Pain, vomiting, nausea, swelling up to knee joint in 4 hrs	10	Absent	11 days Normal	Discharge	2 times
3.	M	28	1.50	R.V. bite	Rigour, throbbing pain, vomiting, nausea, swelling up to elbow joint in 4 hrs	10	Absent	9 days Normal	Discharge	2 times
4.	M	57	2.30	Saw-scaled snake bite	Pain, vomiting twice, nausea, swelling up to shoulder joint in 8 hrs	16	Absent	7 days Normal	Discharge	2 times
5.	M	63	1.30	Krait bite	Ptosis, drowsy, rowdy, giddiness	5	Absent	No swelling Normal	Discharge	2 times
6.	M	47	2.30	R.V. bite	Nausea, abdominal pain, pain, swelling upto thigh in 7 hrs	20	Absent	13 days Normal	Discharge	2 times
7.	M	20	2.15	Brought kill/ green pit viper bite	Nausea, throbbing pain, swelling up to knee joint in 4 hrs	10	Absent	3 days Normal	Discharge	2 times
8.	M	22	1.15	R.V. bite	Bleeding at bite site 2 hrs, nausea, vomiting twice, pain, swelling upto 3 hrs	20	Absent	9 days Normal	Discharge	2 times

9.	M	28	35	R.V. bite having neuro-vascular symptoms	Pain, ptosis, giddiness, nausea, vomiting, swelling up to shoulder joint in 6 hrs	30	Absent	9 days Normal	Discharge	2 times
10.	F	70	3	R.V. bite	Semiconscious, drowsy, rowdy, vomiting, nausea, swelling up to knee joint in 4 hrs	20	Absent	6 days Normal	Discharge	2 times
11.	M	6	1	Brought kill R.V. bite	Pain, nausea, vomiting, swelling up to thigh in 8 hrs	10	Absent	13 days Normal	Discharge	2 times
12.	M	40	0.5	Brought kill R.V. bite	Throbbing pain, nausea, abdominal pain, swelling up to thigh in 8 hrs	30	Absent	9 days Normal	Discharge	2 times
13.	F	65	2.15	R.V. bite	Throbbing pain, chest pain, nausea, vomiting swelling up to thigh in 10 hrs	20	Blister visible after 2 days of bite but no severe necrosis	6 days Normal	Discharge	2 times
14.	F	22	3	Common krait bite	Unconscious, ptosis, giddiness, drowsy, nausea, vomiting	20	Absent	9 days Normal	Discharge	2 times
15.	M	30	1.30	R.V. bite	Throbbing pain, swelling on Lt wrist	25	A minor blister came 2 days after bite only- resolved	6 days	Discharge	2 times

Discussion

The snake mouth is colonised by bacteria that can be transmitted to the bitten patient through the skin injury associated with the bite. Inoculation of bacteria from the micro-teeth in the mouth, fangs, or venom following a snakebite can cause local infection with abscess and necrotising fasciitis in the most severe cases. Local wound infection leads to swelling and necrosis of the bitten tissues mostly of legs or arms that subsequently may require amputation.¹¹ Wound infection following a snakebite usually accounts for 9 to 77% of the patients, as described in several studies. The large differences in the reported prevalence of secondary infections in snakebites can be related to variations in the criteria used to establish the presence of infection. Indeed, there is no precise set of clinical criteria to define infection in snakebite envenomings. In addition, a high proportion of microbiological cultures are negative because of the systematic preemptive use of antibiotics in snake-bitten patients. The main bacteria involved are *Enterococcus faecalis*, *Aeromonas hydrophila* and *Morganella morganii*.¹² Another problem in treating infection is antibiotic resistance to the bacteria that causes infection in snake-bitten patients. In one recent study, isolated *Enterobacteriaceae* following a snakebite infection showed 69% resistance to ampicillin, 60% resistance to amoxicillin/ clavulanate, and 66% resistance to second-generation cephalosporins. In another experimental study examining the bacteria sampled from the oral cavity of 26 *B. lanceolatus*, specimens collected supported the fact that 67% of the isolated bacteria were resistant to amoxicillin/ clavulanate. In addition, the majority of isolated bacteria were susceptible to third-generation cephalosporins (i.e., 73% to cefotaxime and 80% to ceftazidime). Based on the most frequently isolated bacteria and susceptibility profiles documented in cases of infection after snakebite, active antibiotics include third-generation cephalosporins, piperacillin-tazobactam and ciprofloxacin.¹³ In *Naja Naja*, mostly the bacteria are gram negative than gram positive.¹⁴ In another study, oral cavity swabs of 20 snakes representing the Indian cobra, Russell's viper, saw-scaled viper, and common krait were selected and a total of 205 strains were isolated from the oropharyngeal cavity of snakes, which represent the common pathogens, especially *Morganella morganii*, *Escherichia coli*, *Aeromonas hydrophila*, *Pseudomonas aeruginosa*, coagulase-negative *Staphylococcus aureus*, *Bacillus* species, *Micrococcus* species, and some anaerobes including *Clostridium perfringens*.¹⁵ According to a recent study by Velde et al.,¹⁶ traces of *Bothrops* snake venoms were found in necrotic muscle that may call for local bite infiltration of ASV if more evidence is available. Macêdo JK et al.¹⁷ suggest breaking of blisters to drain the venom trapped in them as analysis shows that blister fluids may serve as a reservoir of venom, biologically active proteins/ toxins,

and as such, may indicate the clinical value of removing blister fluid to attenuate further tissue damage. Therefore, we proposed to break these blisters with the pressure of herbal spray as apart from the antiseptic potential of the herbal extract, its antioxidant/ alkaloidal properties¹⁸ help in denaturing venom proteins and neutralising the venom trapped in these blisters. Venom neutralisation of blisters helps contain further damage to local tissues as Jiménez Natalia et al. suggest that Viperid snakebite envenomation induced blistering and dermo-necrosis by a snake venom metalloproteinase BaP1.¹⁹ Metal chelators²⁰ and flavonoids have been demonstrated to induce the inhibition of a snake venom metalloproteinase²¹ (zinc-dependent metalloproteinases) and may have similar action by our herbal extract on stopping blister formation. Scientists support early in situ chelation of venom components at the site of venom injection/ bite site, as inhibition was not as effective as the time lapse between venom and inhibitor injections increased and suggested that administration of peptidomimetic metalloproteinase inhibitors or CaNa2EDTA at the site of venom injection may represent a useful alternative to complement antivenoms in the neutralisation of venom-induced local tissue damage.²² In Brazil, scientists have described the results of several studies of plant extracts and their isolated active principles, which when used against crude snake venoms or their toxic fractions and isolated inhibitors, such as steroids, terpenoids, and phenolic compounds, are able to inhibit PLA2s from different snake venoms.²³

Conclusion

With the success of the pilot using herbal extract at 40 µl concentration in 15 snakebite patients, we intend to produce more extract and get it standardised from the Biotechnology department of HP University and use it in more and more cases to save their lives and limbs. The antimicrobial properties of this herbal extract along with anti-venom and chelating properties make this solution an ideal candidate to be kept at village level health facilities/ PHCs and in ambulances for spray as early as possible at the snake-bitten part to help the patients not to suffer sloughing of muscles and skin, saving them from subsequent skin grafting or amputation. Early the spray is used on snakebite wounds; more is the effectiveness of its action. Uses of this herbal extract for snakebites have been submitted for patent by the authors. Impressed with the magic of this herbal spray, we intend to name it "Jawalaji Spray", jawala meaning flame that burns everything.

Way Forward

The way forward is to use this spray on more and more patients next year so as to generate robust data on the effectiveness of this herbal antibiotic extract and further purify/ concentrate it and try to isolate active ingredients²⁴

of this extract to make it potent antimicrobial and antsnake venom like substance. This herb is commercially available for oral use in the treatment of various ailments²⁵ and we need to explore if its oral use can be of some help to snakebite patients in rural areas where ASV may not be available.

Ethical Statement

No ethical issues are involved here as antibiotics are extensively used in snakebites.²⁶ We routinely give oral/injectable antibiotics to snakebite patients and this herbal extract just supplements this antimicrobial activity at the local level at the wound site where systemic antibiotics may not be effective or local bacteria may be resistant to these oral/parental antibiotics. Informed consent, as routine, was taken from all patients/relatives for treatment of the snakebite before admission to the clinic.

Contributions of the Authors

This unique inter-sectoral team of epidemiologists, snakebite expert doctors, botanical experts, biotechnologists, forest officers, and agriculture scientists contributed equally to the success of this pilot as follows:

The concept of using this plant extract locally as Herbal Extract Cocktail (HEC) on snakebite wounds was developed by Dr Omesh Kumar Bharti, a National Expert on snakebite after an extensive literature review.

Dr Lal Singh is the Chairman of Himalayan Research Group (HRG). HRG, a non-profit society since 1997, is working to generate livelihood for people by preserving and propagating herbal plants.²⁷

HRG has developed a process of extracting a cocktail of herbal antibiotics from an herbal Plant X, produced in Himachal Pradesh by the farmers with the help of the Department of Biotechnology, HP University, Shimla under the guidance of eminent scientist Dr Arvind Kumar Bhatt. This herbal extract has the potential to kill even the most resistant bacteria that are inoculated by a snakebite.

This herbal extract was used locally at the wound site by spray/injection to contain local infection due to snakebite in patients being treated at the Vighnagar Nursing Home Clinic of renowned snakebite experts, Dr Sadanand Raut and Dr Pallavi Raut, at Pune-Nashik Highway near Kukadi Irrigation Colony, A/P Narayangaon Tal Junnar Dist Pune, Maharashtra India. Dr Raut, a National Expert, is in forefront of snakebite mitigation and has formed an NGO named "Vighnagar Foundation"²⁸ for the purpose of snakebite education and mitigation.

We are thankful to Sh. Nagesh Guleria, Chief Project Director, JIKA²⁹ Project Himachal Pradesh, Shimla for his guidance and for assuring financial assistance to this pilot project for the benefit of snakebite victims as well as to local farmers to grow this rare herbal plant for their livelihood.

Our sincere thanks to scientists Dr Maninder Jeet Kaur and Ms Archana Phull for their active discussions and help in writing this manuscript.

Conflict of Interest: None

References

1. Rstmh.org [Internet]. Snakebite: time for collective action; 2018 [cited 2021 Jul]. Available from: <https://rstmh.org/news-blog/blog/snakebite-time-for-collective-action>
2. Suraweera W, Warrell D, Whitaker R, Menon G, Rodrigues R, Fu SH, Begum R, Sati P, Piyasena K, Bhatia M, Brown P, Jha P. Trends in snakebite deaths in India from 2000 to 2019 in a nationally representative mortality study. *Elife*. 2020 Jul 7;9:e54076. [PubMed] [Google Scholar]
3. Joshi S, Mishra D, Bisht G, Khetwal KS. In vitro antimicrobial activity of essential oil of *Swertia cordata* Aerial parts. *Nat Prod J*. 2013;3(1):66-70. [Google Scholar]
4. Thailandsnakes.com [Internet]. Thailand venomous snake skulls - fangs, dentition; [cited 2021 Jul]. Available from: <https://thailandsnakes.com/thailand-venomous-snake-skulls-fangs-dentition/>
5. Kumar V, Staden JV. A review of *Swertia chirayita* (Gentianaceae) as a traditional medicinal plant. *Front Pharmacol*. 2016;6:308. [PubMed] [Google Scholar]
6. Dey P, Singh J, Suluvoy JK, Dilip KJ, Nayak J. Utilization of *Swertia chirayita* plant extracts for management of diabetes and associated disorders: present status, future prospects and limitations. *Nat Prod Bioprospect*. 2020;10(6):431-43. [PubMed] [Google Scholar]
7. Roy P, Abdulsalam FI, Pandey DK, Bhattacharjee A, Eruvaram NR, Malik T. Evaluation of antioxidant, antibacterial, and antidiabetic potential of two traditional medicinal plants of India: *Swertia cordata* and *Swertia chirayita*. *Pharmacognosy Res*. 2015;7(1):S57-62. [PubMed] [Google Scholar]
8. Amazon.in [Internet]. Birju Mahavir Bitter Stick *Swertia Chirata*, Natural, 100 gram; [cited 2021 Jul]. Available from: https://www.amazon.in/Generic-BMKB-Bitterstick-Swertia-Chirata/dp/B079DBLFND/ref=sr_1_43?adgrpid=104710243172&ext_vrnc=hi&gclid=EAlaIQobChMIh6a_6tbJ9AIVGiQrCh0Cp-wNCEAAYASAAEgJc7vD_BwE&hvadid=427033738701&hvdev=c&hvlocphy=9040167&hvnetw=g&hvqmt=b&hvrnd=6551583876399351590&hvtargid=kwd-468926916236&hydadcr=9803_1994216&keywords=chirata+amazon&qid=1638604904&sr=8-43
9. 1mg.com [Internet]. *Chirata*; [cited 2021 Jul]. Available from: <https://www.1mg.com/ayurveda/chirata-188>
10. Mishra MP, Padhy RN. In vitro antibacterial efficacy of 21 Indian timber-yielding plants against multi-

- drug-resistant bacteria causing urinary tract infection. *Osong Public Health Res Perspect.* 2013;4(6):347-51. [PubMed] [Google Scholar]
11. Waiddyanatha S, Silva A, Siribaddana S, Isbister GK. Long-term effects of snake envenoming. *Toxins (Basel).* 2019;11(4):193. [PubMed] [Google Scholar]
 12. Mao YC, Liu PY, Hung DZ, Lai WC, Huang ST, Hung YM, Yang CC. Bacteriology of Najaatra snakebite wound and its implications for antibiotic therapy. *Am J Trop Med Hyg.* 2016;94(5):1129-35. [PubMed] [Google Scholar]
 13. Resiere D, Gutiérrez JM, Névière R, Cabié A, Hossein M, Kallel H. Antibiotic therapy for snakebite envenoming. *J Venom Anim Toxins Incl Trop Dis.* 2020 Feb 3;26:e20190098. [PubMed] [Google Scholar]
 14. Panda SK, Padhi L, Sahoo G. Oral bacterial flora of Indian cobra (*Naja naja*) and their antibiotic susceptibilities. *Heliyon.* 2018;4(12):e01008. [PubMed] [Google Scholar]
 15. Shaikh IK, Dixit PP, Pawade BS, Potnis-Lele M, Kurhe B. Assessment of cultivable oral bacterial flora from important venomous snakes of India and their antibiotic susceptibilities. *Curr Microbiol.* 2017;74(11):1278-86. [PubMed] [Google Scholar]
 16. de Velde AC, Fusco LS, Echeverría SM, Sasovsky DJ, Leiva LC, Gutiérrez JM, Bustillo S. Traces of Bothrops snake venoms in necrotic muscle preclude myotube formation in vitro. *Toxicon.* 2022;211:36-43. [PubMed] [Google Scholar]
 17. Macêdo JK, Joseph KJ, Menon J, Escalante T, Rucavado A, Gutierrez JM, Fox JW. Proteomic analysis of human blister fluids following envenomation by three snake species in India: differential markers for venom mechanisms of action. *Toxins (Basel).* 2019;11(5):246. [PubMed][Google Scholar]
 18. Chauhan RS, Kitchlu S, Kumar A, Dutt P. Variation in the active compounds among natural populations of *Swertiacordata*. *Indian J Nat Prod Resou.* 2018;8(3):224-9. [Google Scholar]
 19. Jiménez N, Escalante T, Gutiérrez JM, Rucavado A. Skin pathology induced by snake venom metalloproteinase: acute damage, revascularization, and re-epithelization in a mouse ear model. *J Invest Dermatol.* 2008;128(10):2421-8. [PubMed] [Google Scholar]
 20. Xie C, Albulescu LO, Bittenbinder MA, Somsen GW, Vonk FJ, Casewell NR, Kool J. Neutralizing effects of small molecule inhibitors and metal chelators on coagulo pathic Viperinae snake venom toxins. *Biomedicines.* 2020;8(9):297. [PubMed] [Google Scholar]
 21. Preciado LM, Comer J, Núñez V, Rey-Suárez P, Pereañez JA. Inhibition of a snake venom metalloproteinase by the flavonoid myricetin. *Molecules.* 2018;23(10):2662. [PubMed] [Google Scholar]
 22. Rucavado A, Escalante T, Franceschi A, Chaves F, Leon G, Cury Y, Ovadia M, Gutierrez JM. Inhibition of local hemorrhage and dermonecrosis induced by *Bothrops asper* snake venom: effectiveness of early in situ administration of the peptidomimetic metalloproteinase inhibitor batimastat and the chelating agent CaNa₂EDTA. *Am J Trop Med Hyg.* 2000;63(5-6):313-9. [PubMed] [Google Scholar]
 23. Carvalho BM, Santos JD, Xavier BM, Almeida JR, Resende LM, Martins W, Marcussi S, Marangoni S, Stábeli RG, Calderon LA, Soares AM, Da Silva SL, Marchi-Salvador DP. Snake venom PLA₂s inhibitors isolated from Brazilian plants: synthetic and natural molecules. *Biomed Res Int.* 2013;2013:153045. [PubMed] [Google Scholar]
 24. Li J, Zhao YL, Huang HY, Wang YZ. Phytochemistry and pharmacological activities of the Genus *Swertia* (Gentianaceae): a review. *Am J Chin Med.* 2017;45(4):667-736. [PubMed] [Google Scholar]
 25. Pharmeasy.in [Internet]. Baidyanath Chirayata Churna - 100 Gm; [cited 2021 Jul]. Available from: https://pharmeasy.in/health-care/products/baidyanath-chirayata-churna---100-gm-236898?utm_source=google&utm_medium=cpc&utm_campaign=Shopping_OTC_Cat_FP_Ayurvedic_Care&utm_adgroup=&gclid=EAIaIQobChMI-bfVzcvE9AIVJClyCh1erwT_EAYYAiABEgKsOfD_BwE
 26. Palappallil DS. Pattern of use of antibiotics following snake bite in a tertiary care hospital. *J Clin Diagn Res.* 2015;9(8):OC05-9. [PubMed] [Google Scholar]
 27. Ngofoundation.in [Internet]. Himalayan Research Group Society in Shimla Himachal Pradesh; [cited 2021 Jul]. Available from: https://www.ngofoundation.in/ngo-directory/himalayan-research-group-society-in-shimla-himachal-pradesh_i13043
 28. Vighnagar Medical Foundation, Pune [Internet]; [cited 2021 Jul]. Available from: <http://www.vighnagarfoundation.org/>
 29. Himachal Pradesh Forest Department [Internet]. JICA Project; [cited 2021 Jul]. Available from: <https://hpforest.nic.in/pages/display/NXNkNGZjhHdkNGY2NQ==jica-project>